Fluid-Fluid Levels in Musculoskeletal Tumor Diagnosis

Achilleas Bekos MD, Spyridon Sioutis MD, Andreas F Mavrogenis MD
First Department of Orthopaedics, National and Kapodistrian University of Athens, School of Medicine, Athens, Greece

Introduction

Fluid-fluid levels are musculoskeletal tumor findings that are most notably observed in MRIs. While previously described as a feature of aneurismal bone cysts, they can occur in several tumorous or non-tumorous lesions.

Pathophysiology

The pathophysiology of FFL formation is conflicting. An ongoing debate exists on whether they are caused by liquefactive necrosis , or unclotted blood from intratumoral hemorrhage.

Imaging

Whereas various imaging modalities exist for the diagnosis of FFLs, MRI is the most sensitive test to date. Although FFLs are best appreciated on fluid-sensitive MR imaging sequences, the optimal sequence is unclear. The CT-Scan, on the other hand, is still an acceptable diagnostic tool, albeit with limitations in detecting differences in density.

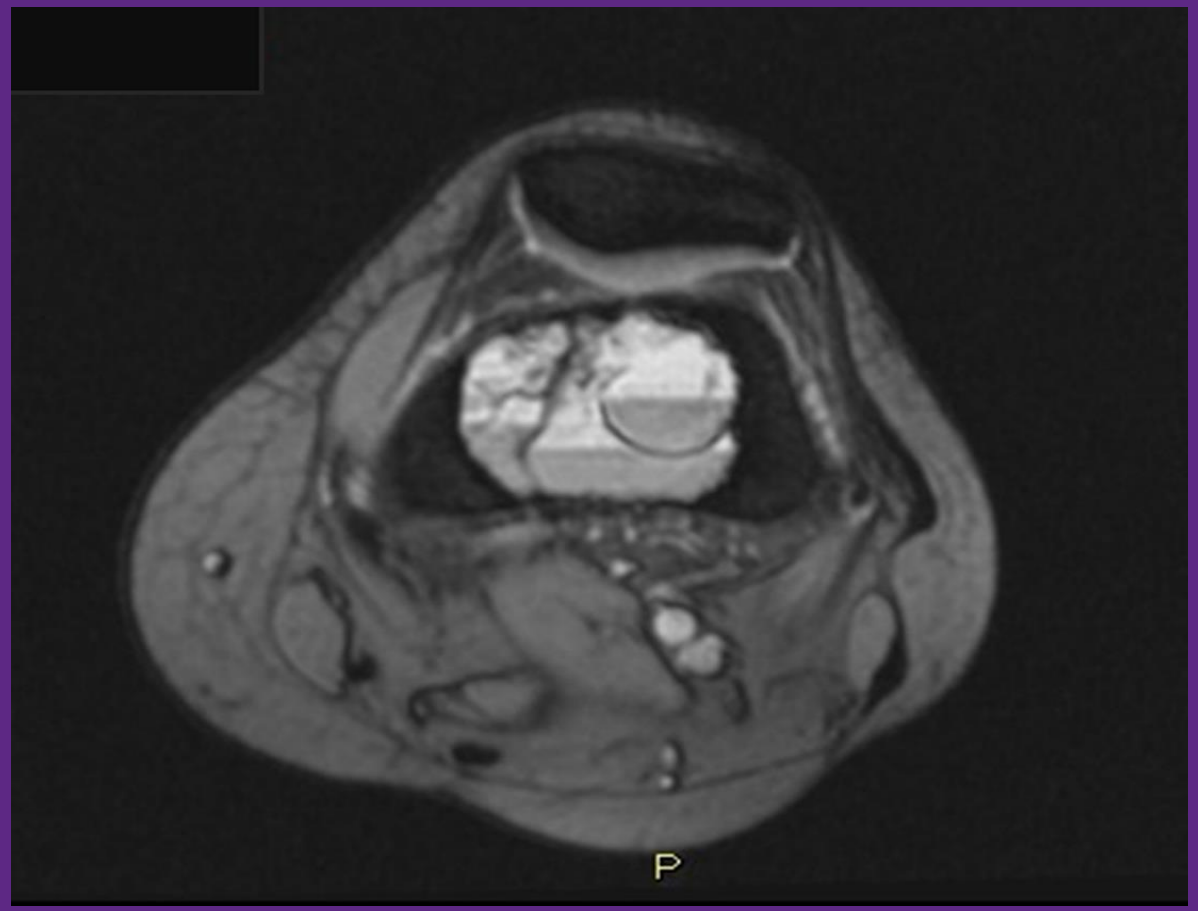

Differential diagnosis in bone tumors

The most common: aneurismal bone cysts and telangiectatic osteosarcoma

Osteosarcomas are characterized by multiple aneurismal dilated cavities that are separated by septations. This feature of nodularity is the key differentiator to the aneurismal bone cyst.

Differential diagnosis in soft tissue tumors

The most common: intramuscular cavernous hemangioma (50%), synovial sarcoma (71%).

Fluid-Fluid Levels in Musculoskeletal Tumor Diagnosis

Achilleas Bekos MD, Spyridon Sioutis MD, Andreas F Mavrogenis MD
First Department of Orthopaedics, National and Kapodistrian University of Athens, School of Medicine, Athens, Greece

Differential diagnosis in non-tumor entities

Several non tumor entities can present with FFLs, most notably intraosseous ganglia, lipohemarthrosis, osteomyelitis, hematomas and epidermal cysts. In intraosseous ganglia we suppose that the myxomatous tissue accounted for the dependent fluid level, with the serous fluid floating on top. On the other hand, in lipohemarthrosis fat and blood are the two components. In the case of osteomyelitis, observation on CT of fluid levels within the medullary cavity of the long bones and the adjacent joint spaces, may suggest the presence of pus and be a pathognomonic sign.
Cystic lesions such as tumors with liquefactive necrosis or bleeding, chronic hematomas, epidermal cysts may show FFL. When FFLs are noted in hematoma, the supernatant layer may be hypointense, isointense, or hyperintense relative to the dependent layer on T1.

Prediction on prognosis

The presence of FFL is a non-specific observation. The extent of FFL within a focal bone lesion has been shown to be inversely related to the degree of malignancy. If only a small proportion (<1/3) of the lesion is occupied by FFL, the majority (67%) of diagnoses are malignant, most commonly osteosarcomas. Furthermore, presence of FFL on MR imaging in osteorsarcomas is an important negative independent risk factor associated with chemo-resistance.

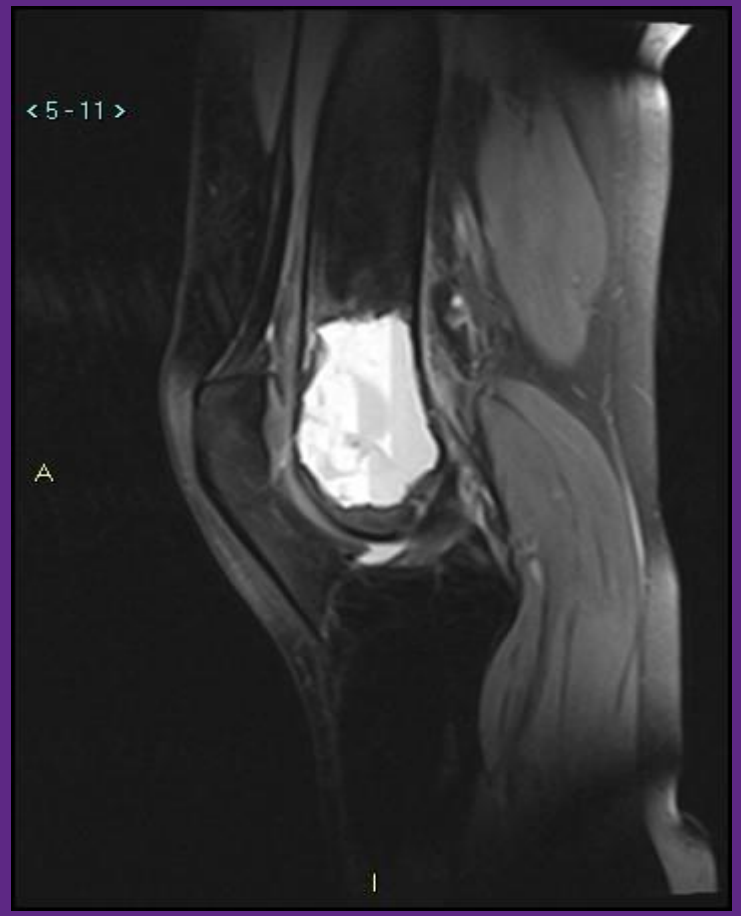

Conclusion

FFL are more common in bone compared to soft-tissue tumors, most commonly in ABC and osteosarcoma. They may be observed in a wide variety of tumor and non-tumor entities.
FFL should not be considered a specific imaging finding of any particular type of tumor.
The diagnosis should be made on the basis of other radiological and clinico-pathological findings of the lesion